

Pakistan J. Zool., vol. 47(5), pp. 1492-1494, 2015

Macroanatomical Investigation on the Ossa Membri Pelvini of Anatolian Bobcat, *Lynx lynx*

Ozcan Ozel* and Mevlut Aykut

Department of Anatomy, Faculty of Veterinary, Mehmet Akif Ersoy University, Burdur, Turkey

Abstract. The aim of the study was to investigate hind limb bones of a dead adult female bobcat. Fossa acetabuli was deep and incisura acetabuli was formed as wide notch. There was only one protrusion on tuber ischiadicum. It was observed that caput ossis femoris was located more proximal than trochanter major. Tuberositas supracondylaris was determined on the proximal direction of condylus lateralis. Tibia and fibula were completely shaped and had proximal and distal articulations. Joint surface of cochlea tibia observed in oblique form. Two tarsal bones in the proximal and four tarsal bones in the distal row of ossa tarsi were observed. Five metatarsal bones were observed; the first one was rudimentary while the remaining four were in developed form. In conclusion, hind leg bones of bobcat were investigated to complete deficient literature data.

Key words: Anatolian Bobcat, ossa membri pelvini, macroanatomy.

Although there has been a large number of studies on wild animals (Atalar and Ozdemir, 2002; Dinc and *et al.*, 1999; Girgin *et al.*, 1988; Gultekin and Ucar, 1980; Karan, 2012; Ozdemir and Karan, 2001; Ozdemir and Atalar, 2003), there no study on hind limb bones of Anatolian bobcat, *Lynx lynx* family Felidae. It was aimed to investigate ossa membri pelvini of bobcat skeleton system since no information is available on this subject.

Material and methods

The study was based on examination of a dead adult female lynx found in Altinyayla district

boundaries. Digital caliper (150 mm.) was used for measurement of bones according to Tasbas and Tecirlioglu (1966). Terminology used in this study comes from Nomina Anatomica Veterinaria published in 2012.

Result and discussion

Symphysis pelvina was 52.08 mm long. Fossa acetabuli was deep in line with the literature (Atalar and Ozdemir, 2002; Evans and Christensen, 1979; Getty, 1975) and incisura acetabuli was in the form of a wide notch (Dinc *et al.*, 1999; Getty, 1975; Ozdemir and Karan, 2001; Ozdemir and Atalar, 2003). Karan (2012) reports that incisura acetabuli was narrow in pigs. Ala ossis ilii of each os coxae was parallel to the median plane. There was a deep cavity on facies glutea in cranio-caudal direction. Crista iliaca has a convex and thick edge. Unlike what was reported by Ozdemir and Karan (2001), tuber ischiadicum in bobcat was in the form of one ridge in line with the literature (Atalar and Ozdemir, 2002; Dinc *et al.*, 1999; Ozdemir and Atalar, 2003). Spina ischiadica was blunt; its caudal tip gets thicker towards ischiadica minor. Eminentia iliopubica were prominent as reported by Gultekin and Ucar (1980) and Girgin *et al.* (1988) and were located at the center of the distance between frontal tip of symphysis pelvina and corpus ossis ilii (Fig.1).

Although it has been reported that caput ossis femoris was aligned with trochanter major in lynx (Atalar and Ozdemir, 2002; Dyce *et al.*, 2002; Evans and Christensen, 1979; Getty, 1975; Gultekin and Ucar, 1980; Karan, 2012; Ozdemir and Atalar, 2003 ;Ozdemir and Karan, 2001; Dinc *et al.*, 1999), ossis femoris was found located more in proximal part of trochanter major. Fossa trochanterica was very obvious. Trochanter minor was in the form of a highly prominent ridge in caudodistal part of caput femoralis on medial end (Fig. 2). While tuberositas supracondylaris was found to be present proximal to condylus lateralis, which is found in distal section of femur as reported by several researchers (Dinc *et al.*, 1999; Evans and Christensen, 1979; Girgin *et al.*, 1988; Gultekin and Ucar, 1980; Ozdemir and Karan, 2001), Karan (2012). Facies articularis sesamoidea lateralis et medialis, which is found proximal to the caudal end of condylus lateralis (Getty, 1975) was

* Corresponding author: ozcangel@gmail.com

ozcanozgel@mehmetakif.edu.tr

0030-9923/2015/0005-1492 \$ 8.00/0

Copyright 2015 Zoological Society of Pakistan

not found in this study. Similar to the studies of Ozdemir and Karan (2001) and Karan (2012), trochanter tertius was not found in the present study.

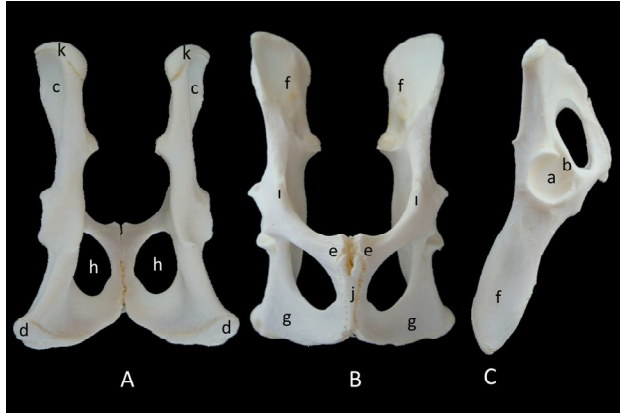


Fig. 1. Macroscopic image of bobcat coxae. A, dorsal aspect; B, ventral aspect; C, lateral aspect. Fossa acetabuli (a), incisura acetabuli (b), facies glutea (c), tuber ischiadicum (d), os pubis (e), os ilii (f), os ischii (g), foramen obturatum (h), symphysis pelvina (j), crista iliaca (k), eminentia iliopubica (l).

Basis patella was large and blunt while apex patella more pointed and roughly. Although patella had a triangular shape in bobcat, it was oval as described by different researchers (Atalar and Ozdemir, 2002; Dinc *et al.*, 1999; Ozdemir and Karan, 2001; Ozdemir and Atalar, 2003).

Tibia and fibula were fully formed, which have a large distance between them. They were observed to articulate from proximal and distal ends (Atalar and Ozdemir, 2002; Evans and Christensen, 1979; Getty, 1975; Karan, 2012; Ozdemir and Karan, 2001; Ozdemir and Atalar, 2003). Eminentia intercondylaris was well developed. Similar to the studies of Dinc *et al.* (1999) and Atalar and Ozdemir (2002), joint surface in cochlea tibia was oblique, although it was reported to be sagittal in the literature (Evans and Christensen, 1979; Getty, 1975; Karan, 2012; Ozdemir and Atalar, 2003). Fibula was in the form of a thin rod, and extends to the distal end maintaining its thickness. The ends of fibula that join with tibia at proximal and distal ends get thicker. Distal surface of fibula has the joint surface where os malleolare was found (Fig. 3).

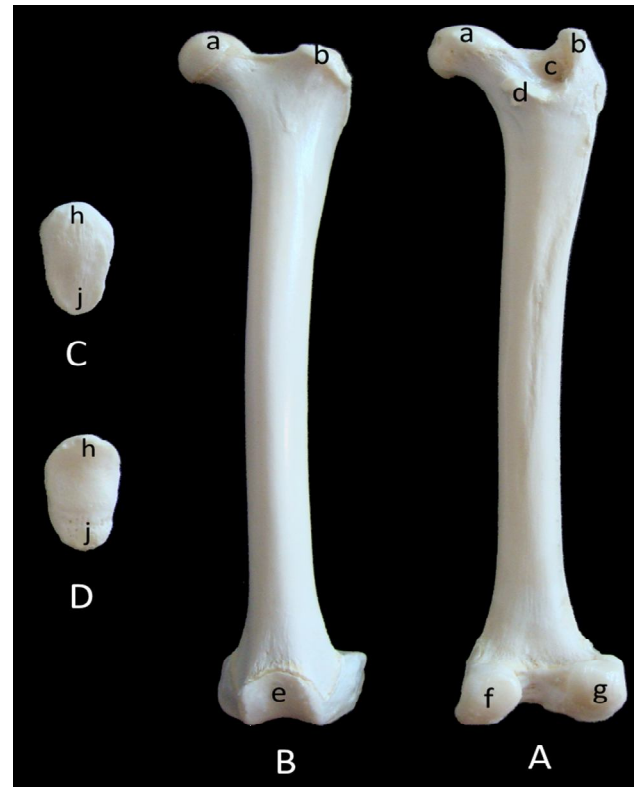


Fig. 2. Macroscopic image of bobcat femur and ossa sesamoidea. A, back aspect of right femur; B, front aspect of left femur; C, Lateral aspect of os sesamoidea; D, Medial aspect of os sesamoidea. Caput ossis femoris(a), trochanter major(b), fossa trochanterica(c), trochanter minor(d), trochlea ossis femoris(e), condylus medialis(f), condylus lateralis(g), basis patella(h), apex patella(j).

There was an apparent groove on tuber calcanei of calcaneus, which was found in proximal row and there was a deep transverse line at the central point of the surface where this groove was present. Trochlea tali, which was in distal of tibia, has a semi-cylindrical oblique joint surface. There were four tarsal bones with no bonding in distal row, which were termed as os tarsale I, II, III and IV. Furthermore, its reported in the literature (Dyce *et al.*, 2002; Evans and Christensen, 1979; Getty, 1975; Karan, 2012) that there was another bone called os tarsi central between proximal and distal row bones. There were five metatarsal bones, the first one of which was rudimentary, while other four were

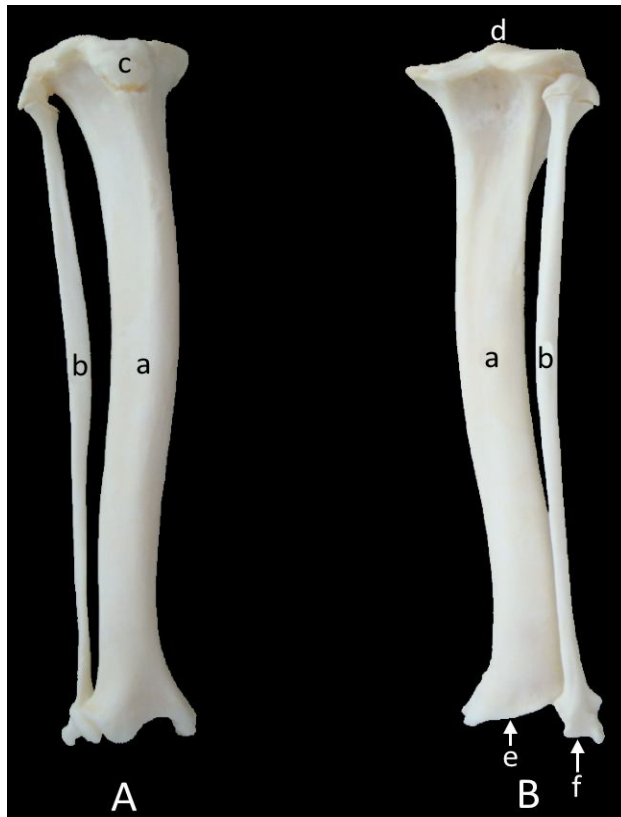

Fig. 3. Macroscopic image of bobcat ossa cruris. (A): Front aspect of right ossa cruris; (B): Back aspect of right ossa cruris. Tibia(a), fibula(b), tuberositas tibia(c), eminentia intercondylaris(d), cochlea tibia(e), distal end of fibula(f).

developed (Atalar and Ozdemir, 2002; Dinc *et al.*, 1999; Evans and Christensen, 1979; Getty, 1975; Karan, 2012; Ozdemir and Karan, 2001; Ozdemir and Atalar, 2003). The lengths of these bones were in descending order were os metatarsale III, os metatarsale IV, os metatarsale II, os metatarsale V and os metatarsale I, phalanx proximalis, phalanx media and phalanx distalis were present in each finger. Although phalanx proximalis was slightly longer, the length of phalanx proximalis and phalanx media were almost the same. Although it was reported that phalanx distalis was small for Atalar and Ozdemir, (2002), similar to Ozdemir and Karan (2001) and Ozdemir and Atalar (2003), as bobcat have stronger claws, phalanx distalis, which was the bone where the claws were found, was observed to be highly developed (Fig.4).

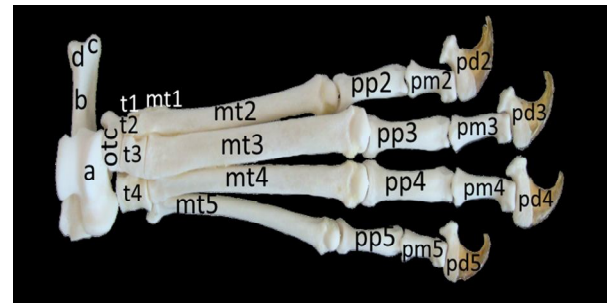


Fig. 4. Macroscopic image of bobcat tarsal bones, metatarsal bones and phalanges. Talus(a), calcaneus(b), tuber calcanei(c), deep groove on tuber calcanei(d), os tarsi centrale (otc), tarsal bone(t), metatarsal bone(mt), phalanx proximalis(pp), phalanx media(pm), phalanx distalis(pd).

In conclusion, hind leg bones of bobcat were investigated to complete deficient literature data.

References

- Atalar, O. and Ozdemir, O., 2002. *Firat Univ. Vet. J. Hlth. Sci.*, **16**: 233-236.
- Dinc, G., Aydin, A. and Atalar, O., 1999. *Firat Univ. Vet. J. Hlth. Sci.*, **13**: 229-232.
- Dyce, K.M., Sack, W.O. and Wensing, C.J.G., 2002. *Textbook of veterinary anatomy*. Third Edition, Saunders, Philadelphia, pp. 467-476.
- Evans, H.E. and Christensen, G.C., 1979. *Miller's anatomy of the dog*. Second Edition, W.B. Saunders Company, Philadelphia, pp. 197-222.
- Getty, R., 1975. *Sisson and Grossman's the anatomy of the domestic animals*. Volume 2, Fifth Edition, W.B. Saunders Company, Philadelphia, pp. 1452-1467.
- Girgin, A., Karadag, H., Bilgic, S. and Temizer, A.K., 1988. *J. Vet. Sci. Selcuk Univ.*, **4**: 169-182.
- Gultekin, M. and Ucar, Y., 1980. *J. Facult. Vet. Med. Ankara Univ.*, **27**: 201-214.
- International Committee on Veterinary Gross Anatomical Nomenclature, 2005. *Nomina Anatomica Veterinaria (N.A.V.)*, 5th ed. World Association of Veterinary Anatomists, Hannover, Columbia, Gent, Sapporo.
- Karan, M., 2012. *Firat Univ. Vet. J. Hlth. Sci.*, **26**: 31-34.
- Ozdemir, O. and Karan, M., 2001. *Firat Univ. Vet. J. Hlth. Sci.*, **15**: 397-400.
- Ozdemir, O. and Atalar, O., 2003. *Firat Univ. Vet. J. Hlth. Sci.*, **17**: 151-154.
- Tasbas, M. and Tecirlioglu, S., 1966. *J. Facult. Vet. Med. Ankara Univ.*, **12**: 324-330.
- <http://www.tramem.org/memeliler/?fsx=2fsdl17@d&tur=Va% C5%9Fak>

(Received 11 February 2015, revised 9 April 2015)